

Immunoadsorption in Lupus

Myocarditis

Griveas I.¹, Visvardis G.¹, Zarifis I.², Papadopoulou D.¹,
Manou E.¹, Kyriklidou P.¹, Nouskas I.², Mitsopoulos E.¹,
Sourgounis A.², Meimaridou D.¹, Ginikopoulou E.¹,
Sakellariou G.¹

**Departments of Nephrology¹ and Cardiology²,
Papageorgiou General Hospital, Thessaloniki,
Greece**

INTRODUCTION (I)

- Systemic lupus erythematosus (SLE) is an autoimmune disease involving between 20 to 50 patients per 100.000 population in which the mortality still exceeds healthy controls three times
- Cardiovascular manifestations in SLE patients are common and represent the third leading cause of death

Feldman A, McNamara D. Medical progress: Myocarditis (review). N Engl J Med 2000; 343: 1388-1398

INTRODUCTION (II)

- Myocarditis is clinically diagnosed in less than 10% of SLE patients, and incidence is reported to have decreased to 7% in recent post mortem studies
- Fulminant myocarditis with cardiogenic shock in lupus patients is very uncommon and there are a few anecdotal reports of such cases
- The pathogenesis of myocarditis in SLE has been ascribed to many factors (autoimmunity, 40% in necrotomic findings, medications (steroids) and coexisting diseases)

AIM OF THE STUDY

- We present a rare case of fulminant SLE myocarditis with pericardial tamponade which reversed after pericardiotomy, treatment with steroids, cyclophosphamide and iv immunoglobulin combined with IA therapy, an extracorporeal method of purifying the blood in which the components of the immune system are specifically removed from the blood

CASE REPORT

- An 29 – year – old – man was presented with fever (39,3°C) and night sweats during the last 15 days, joint swelling and pain, fatigue (the last 4 months), weight loss (10 kgr in 6 months), lymphadenopathy and morning stiffness
- His personal and family history, initial laboratory studies were free of any specific findings

Laboratory values at the first admission of the patient

WBCs	5.380/mm ³
Hemoglobin (Hb)	13 g/dl
Platelet count (PLT)	333.000/mm ³
Creatinine	0,69 mg/dl
Blood urea nitrogen (BUN)	36 mg/dl;
ESR	28
Rheumatoid factor	normal values
Thyroid hormones	normal values
C reactive protein (CRP)	normal values

-
- Thoracic and abdomen computed tomography revealed enlarged lymph nodes and elevated size of the spleen
 - He was treated with antibiotics, fever resolved and the patient dismissed for 15 days

10th day: high fever (39° C), mostly at night
criteria of SLE seemed applicable
Steroids

Laboratory values in the 10th day

WBCs	4400K/ μ l
Hct	36,9%
Hb	12,3g/dl
PLT	323 K/ μ l
CRP	2,02mg/dl (normal values < 0.8)
Blood cultures and viruses detection	negative
C3	94 mg/dl (normal,79-152 mg/dl)
C4	21,6 mg/ml (normal 16- 38 mg/ml)
Antinuclear antibody (ANA) titer equal to 1:5120 and positive lupus anticoagulant panel.	
Urinalysis	specific gravity of 1,025, p H 5,1+
blood and 2 to 5 RBCs/high –powered field	

- ***15th day***: high fever (39° C), anemia, cytopenia (cyclophosphamide 0,5 i.v.).
- Transoesophageal echocardiography test showed modest mitral regurgitation (1+/4+)

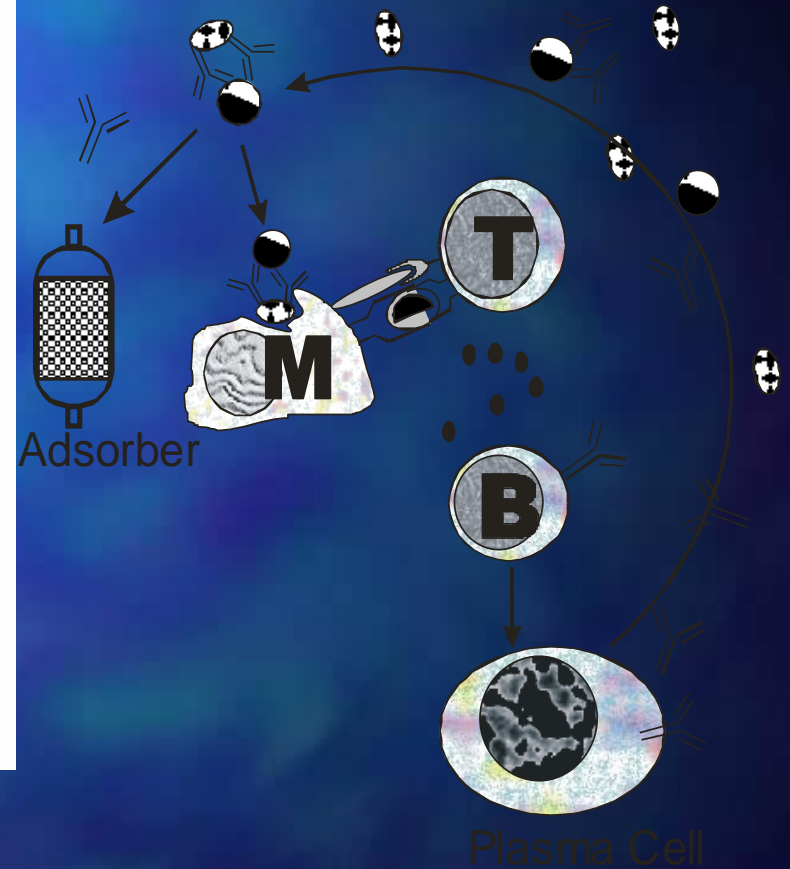
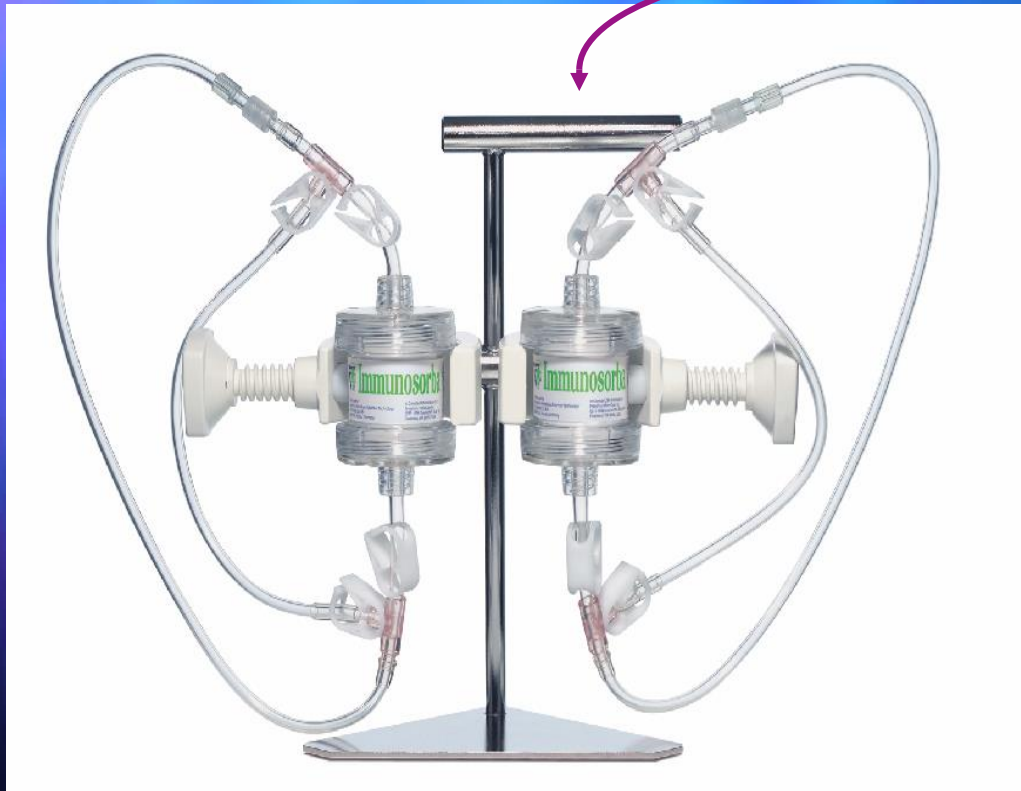
- **20th day:** patient deteriorated, hypotension, tachypnea, increased heart rate, interstitial pleural edema and pericardial effusion
- A new echocardiographic test showed impaired contractility of the left ventricle , a large pericardial effusion and diastolic collapse of the right cavities , corresponding with pericardial tamponade

-
- Pericardiectomy - coronary care unit
 - Patient was treated with steroids (prednisone 75mg/day i.v.) ,cyclophosphamide (0.5mg i.v.), ACE inhibitors (captopril 62.5mg/day), diuretics (furosemide 60 mg/day i.v.) and underwent 5 plasmapheresis sessions

- **After 8 days in coronary care unit**, fever ,edema and effusion were resolved, his heart rate improved but echo findings remained the same (ejection fraction: 35%)
- **After 12 days under intensive care** his clinical and laboratory features got worse (ejection fraction: 25%, LVEDD 55 mm, MR 2+/4+) - immunoadsorption onto staphylococcal protein A

(Excorim Immunoadsorption System consists of two Immunosorba columns used with Citem 10, Fresenius Hemocare)

The pathoimmunological circle



- **In the 14th day:** cardiogenic shock - intubation (initropes and intraortic balloon pump)
- **In the 18th day** patient's hemodynamic status had improved and was discharged from mechanical ventilation , but responded with psychotic episode

- Status epilepticus was established **in the 19th day**
- In the end of immunoadsorption therapy laboratory tests included ANA titer, negative; anti-DNA titer 1:2560; C3 103 ;C4 31,10
- **After 77 days** of hospitalization patient responded well, his clinical condition had been improved with normal heart rate, without fever and with ejection fraction 45-50%

DISCUSSION(I)

- Our patient had a rapidly accumulated pericardial effusion that led to tamponade and severe myocardial dysfunction evolving to cardiogenic shock, after tamponade was treated
- Our diagnosis was lupus carditis, based on the patient's history (fever, serositis, neurologic disorder) and laboratory tests (anemia, thrombocytopenia, positive antinuclear antibodies and lupus anticoagulant)

DISCUSSION (II)

- Lupus myocarditis is attributed to an immune-complex mediated phenomenon, since granular immune-complex and complement deposition has been found in the walls and perivascular tissues of myocardial blood vessels
- Antimyocardial and other circulating autoantibodies (antiribonucleoprotein, anti-Ro, antiphospholipid) have been detected in SLE myocarditis patients, but their role remains uncertain
- Either mechanism may provoke the autopsy findings in lupus myocarditis: small vessel vasculitis, focal myocarditis, fibrosis and interstitial necrosis

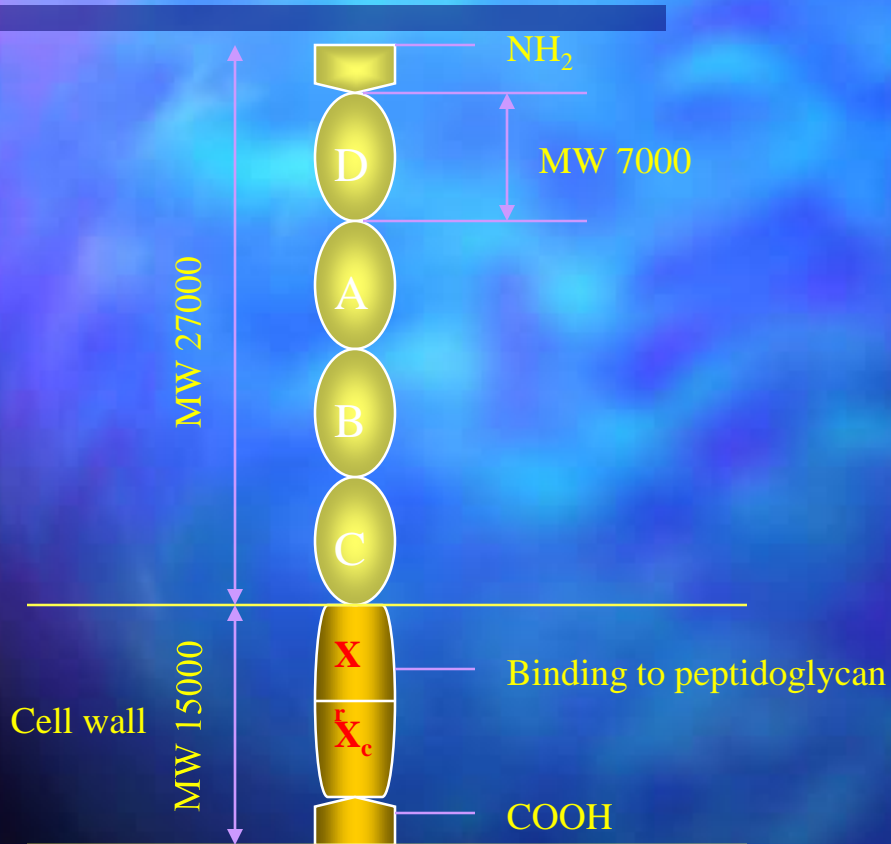
DISCUSSION (III)

- Fulminant lupus myocarditis is a rare condition
- Our patient developed severe lupus myocarditis combined with pericardial tamponade; there has been no previous report of such a combination (Pericardial tamponade has been reported in 0,8% in SLE patient series)
- The condition of the patient deteriorated despite the reversal of tamponade, due to a rapid impairment of myocardial contractility that led to cardiogenic shock
- Treatment of such cases is mainly based on clinical experience rather than randomized trials

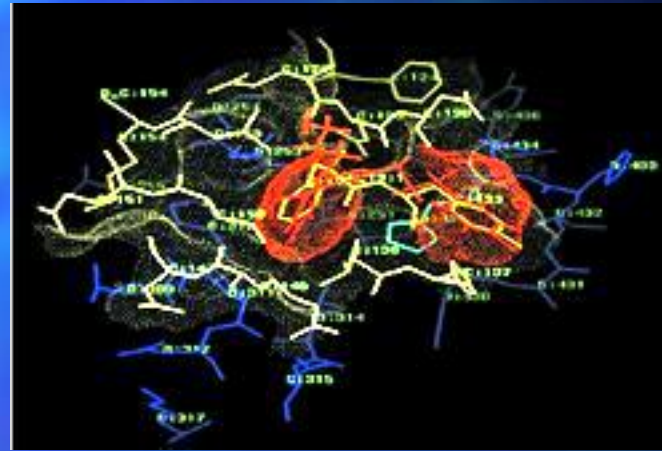
DISCUSSION (IV)

- Immunomodulation using plasma perfusion over a staphylococcal protein A silica matrix column is reported to induce favorable responses in autoimmune diseases
- The mechanism of action is not completely clear but may involve selective removal of circulating immune complexes or IgG that is exerting an adverse immunologic effect
- Immunoabsorption onto staphylococcal protein A has been shown to be a powerful tool on patients with severe SLE which were resistant to conventional immunosuppressive therapy (*Braun et al.Nephrol. Dial. Transpl.2000 (15) 1367*)

Protein A



Staphylococcus protein a (SPA)



Protein a
IgG
Biomimetic

- Interaction between IgG protein a via CH2 and CH3 domain of IgG (F_c-fragment)
- Some binding affinity to the Fab-fragment
- Binds IgG(1,2,4) not IgG3
- Binds some IgM and IgA (Fab fragment)
- High affinity to CIC

DISCUSSION (V)

- On the other hand there are not data which refer to immunoadsorption as a therapeutic choice in myocarditis of SLE
- At the same time there are papers which establish immunoadsorption as an accepted therapy for Dilated Cardiomyopathy (DCM) patient
- The pathophysiology of myocarditis and DCM with regard to apoptosis was described by *Alter et al (2001)*
- The authors observed increased apoptosis in both diseases being highest in severe active myocarditis
- *Strangl et al (2000)* tried to improve cardiac function by using immunoadsorption in DCM patients with promising results

CONCLUSIONS (I)

- Life- threatening exacerbations of SLE, such as myocarditis can endanger the function of vital organ systems and require massive immunosuppressive treatment
- Apart from this kind of treatment plasmapheresis has been offered without the proper results in all the cases
- On the other hand, lupus myocarditis with complications as shock and tamponade, is a severe situation lacking a satisfying efficient therapy available today

CONCLUSIONS (II)

- In our presenting case selective immunoglobulin removal techniques (IA) was beneficial
- The intention was to control the immune system in this disease and IA achieved it, probably with the usefull co-medications
- Considering the benefits in our case and the current knowledge, it might be usefull to clarify the open questions in scale pilot studies